

EXTENSIVE ORAL CANDIDIASIS WITH ANTERIOR FAUCIAL PILLAR PERFORATION

A 50-year-old female patient presented to Department of Medicine, Military Hospital Palampur

Himachal Pradesh, India, in August 2013, with a history of significant weight loss, loss of appetite and dysphagia for past three months. She was, a diagnosed case of immune surveillance since 2010 with initial CD4 count of 50, on ART (Tenofovir, Lamivudine and Nevirapine) with no history of opportunistic infections and poor drug compliance .

She had a BMI of 16 Kg/m² , oral candidiasis with anterior faucial pillar perforation(Fig1). Scappings stained with PAS confirmed candidiasis (Fig2).Candida was also grown on agar(Fig3). CD4 count was 6. She was restarted on ART , septan and fluconazole. Blood sample sent for ART resistance.

The prevalence of oral candidiasis among AIDS patients is estimated to be between 9% and 31%. There have been seven reported cases of gastrointestinal perforation associated with Candida infection,¹ most of which were immune compromised patients. There has been no reported case of invasive oral candidiasis.

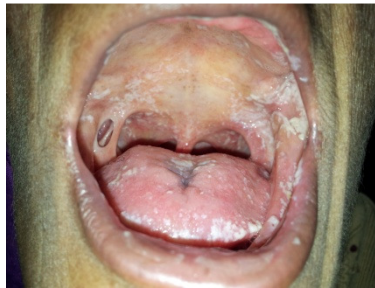

Fig 1. Extensive oral candidiasis with anterior faucial pillar perforation




Fig2.Candida growing on agar(from oral scrapings)

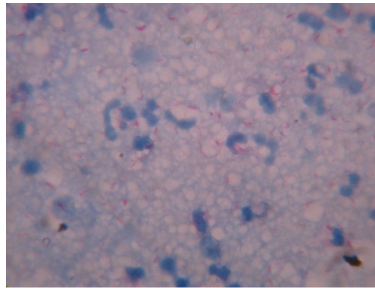


Fig3. Candida stained with periodic acid Schiff

REFERENCE

1. Baha Al-Shawwa, Lynn D'Andrea, Diana Quintero. Candida esophageal perforation and esophageal pleural fistula, a case report. J Med Case Reports. 2008; 2: 209.

Guleria Vivek .S, Rana Tanuja, Sharma Ajay, Kumar Virendra

VS Guleria Military Hospital Palampur Himachal Pradesh

Corresponding contributor: Maj VS Guleria, Military Hospital Palampur Himachal Pradesh