

## A rare case of deep penetration of skull base by an airgun pellet

### ABSTRACT

Seemingly harmless low velocity weapons like air guns sometimes may cause deep penetration of tissues leading to serious disability or even death especially in children. Deep penetration is rare in adults. We present a case of penetration of anterior skull base by air gun pellet in an adult in whom the projectile could not be retrieved initially but became accessible for removal due to spontaneous expulsion after two years of injury. Relevant literature about etio - pathogenesis and management of such cases is reviewed.

**Key Words:** air gun, skull base, sphenoid sinus, penetrating injury, projectile

### INTRODUCTION

An airgun can be a rifle, pistol or similar weapon / toy which fires projectiles by means of compressed air or gas. In contrast to this, a firearm burns gun powder or a similar propellant to fire its projectile device. Most airguns use metallic projectiles called as pellets. These are considered low velocity rifles and are generally regarded as safe. These are in wide use for hunting / sports / fun games or pest control and do not require a licence in many countries. However, sometimes these seemingly harmless weapons can cause severe, disabling and even fatal injuries.<sup>1-3</sup>

Fatalities are more likely if pellets have penetrated the head, neck or chest. Shaw and Galbraith reported two deaths from penetrating airgun injuries of head - subdural haematoma in a three year old boy and rupture of an abscess surrounding a pellet 19 months after initial injury in a 15 year old boy.<sup>4</sup> Air embolism of the pellet / bullet can also occur.<sup>5</sup>

Air weapon injuries typically involve teenage boys<sup>6</sup> and are relatively uncommon in adults. Further, due to low velocity and low kinetic energy deep penetration of tissues by airgun pellets is also rare. We present a case which was uncommon on both these accounts – an adult with deep penetration of skull base by airgun pellet.

### Case Report:

A 36 year old male presented to us with complaints of severe bleeding from both nostrils as well as mouth and severe headache after allegedly being bitten by an insect close to right eye about half an hour back. On examination the patient was in shock with evidence of bleeding from both nasal cavities. The patient was resuscitated. Detailed evaluation thereafter revealed no insect bite mark anywhere on the face but there was a 2 mm sized wound in the skin just medial to medial canthus of right eye and mild ecchymosis under right lower eye lid [Fig 1]. There were no other injury marks. There was no neurological deficit. Visual acuity was impaired in right eye (6/60) and normal in left eye. Eye movements were normal. Nasal endoscopy revealed blood in both nasal cavities along with destruction of ethmoid air cells on both sides. Bleeding had stopped. For further evaluation CT study of paranasal sinuses (PNS) and Head was performed which showed high density foreign body resembling air gun pellet encroaching Rt cavernous sinus. There was a fracture in anterior wall of sella. Blood density fluid was present in ethmoids and sphenoid sinuses bilaterally [Figs 2-3]. Herniation of soft tissues through the floor of the orbit into right maxillary sinus was noted [fig 4]. The patient was then specifically enquired about the possible air gun injury, at which he

confirmed that there were some people firing air guns near by to drive the monkeys away and he had heard the sound of shots being fired when the 'insect bit him'. This left no doubt that an airgun pellet had struck the patient accidentally.

Parenteral antibiotics were started and the patient was taken to Operation Theatre where local wound debridement and Endoscopic clearance of all blood from PNS was performed and damaged air cells were excised. Sphenoid sinus was entered by widening its ostia medially and inferiorly. There was a mucosal tear in its roof but foreign body was not visible or palpable in the sphenoid sinus walls or cavity, hence removal could not be attempted. After the procedure the patient's headache subsided completely and vision in right eye improved to 6/18 by next day. Neurosurgeon's opinion was sought for possibility of removal of foreign body via a neurosurgical approach, who advised against any such attempt due to great risk of optic nerve injury / severe bleeding especially when the patient was asymptomatic and his vision had already improved to great extent.

The patient thereafter was advised quarterly follow up. Over next two years he remained asymptomatic and showed no evidence of migration / infection of foreign body or any lead toxicity. However, after two years he started having momentary smarting pain over his vertex hence reported for check up before the scheduled follow up. Endoscopic examination performed through previously enlarged sphenoid ostium showed the pellet projecting into the sphenoid sinus from postero-lateral part of its roof. Gentle palpation of the foreign body revealed it to be quite loose. With little more careful and gentle manipulation it was delivered into the cavity of the sinus from where it was picked up easily and removed. No significant bleeding occurred due to the procedure. The patient again became symptom free thereafter but was lost to follow up after six months.

## DISCUSSION

Injuries due to bullets / pellets / splinters and other projectiles are broadly divided into High Energy and Low Energy Missile Injuries depending on the velocity at which the projectile travels.

High Energy Missiles travel at a speed in excess of 2000 ft/s. These inflict damage on human tissues by the processes of shock wave, temporary cavitation and permanent cavitation. The result of this can be comminuted fractures or a hole formation due to perforative impact. Bone fragments can act as secondary missiles causing much more damage than the original projectile.

Low Energy Missile Injuries as in case of air guns result at velocities below 1500 ft/s and are caused by mechanisms different than High Energy Missiles. These mechanisms include direct injury to tissues, such as laceration and crushing within the missile tract, rather than the effects of temporary cavitation.<sup>7</sup>

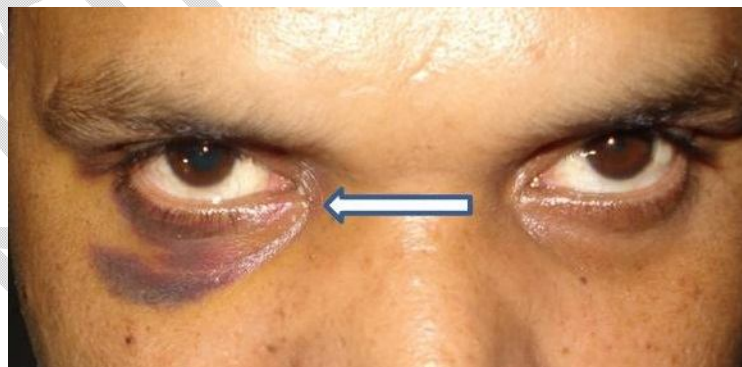It is estimated that the critical velocity required for penetration of human skin by an air rifle pellet is around 125–230 ft/s (38–70 m/s).<sup>8</sup> However, it should be noted that muzzle velocity alone is not the only factor determining the damage to the target tissues. The pellet velocity when it enters the tissues is more determinative of tissue damage caused. The tissue damage and depth of penetration will also depend on tissue characteristics like the strength, consistency, thickness and type of tissues etc. When Low Energy Missiles enter through medial wall of the orbit and ethmoids air cells, very less resistance is offered by thin papery bones of these structures allowing deep entry even into intracranial tissues. This can result in severe disability like blindness, neurological disability or even death.

Skurczynski demonstrated that air rifles can develop enough power to cause projectiles to penetrate the skull, depending on the distance between the weapon and the penetrated tissue.<sup>9</sup> Literature reveals that most such cases involve children below 16 years of age with boys more commonly affected than girls.<sup>10,11</sup> Deep penetration in case of adults has been reported only in few cases.<sup>12</sup> Common sites of entrance for such cases have been reported as eye, temple or forehead.

Most of the surgeons believe that lodged pellets should be removed as far as possible by external or endoscopic approach, however this issue is debatable. Remarkable recovery allowing return to pre injury job despite the bullet still lodged in brain has been reported.<sup>13</sup> Many other researchers have also questioned retrieval of pellet and advocated conservative approach particularly where the risks are more than leaving the pellet in situ, reserving retrieval only if a nerve injury or life threatening vascular injury is present.<sup>14-16</sup> Such decisions should be taken on case to case basis, weighing the pros and cons carefully. Holland et al reported three cases of penetrating airgun injuries to the neck - two had the pellet removed and one had conservative management.<sup>17</sup> In general, foreign body may be left undisturbed if retrieval involves risk to important structures like optic nerve and internal carotid artery. Skull base projectiles require special vigilance for possible cerebrospinal fluid leakage.<sup>18</sup> Selective angiography may be useful in detecting vascular injury. Neuronavigation system may be useful in localising the projectile during retrieval. Prophylactic antibiotic coverage, analgesics, local wound debridement and eye care (if involved) are recommended for all patients.

Long term sequelae of retained foreign body in Head – Neck area include chronic sinusitis, rhinolith formation, meningitis, chronic pain syndrome and even malignancy.<sup>3,19,20</sup> There is theoretical risk of lead poisoning also.

Our case highlights that deep penetration by Low Energy Missiles is not necessarily limited to children and can occur even in adults. Tissue characteristics of the areas coming in the path of the projectile will decide the depth of penetration and damage. Further, results of thoughtfully decided conservative management may be more rewarding than hasty retrieval of the projectile, as illustrated by our case. We recommend enactment of suitable laws and creation of awareness in masses about potentially injurious nature of air rifles/ air guns for prevention of such injuries.



**Fig 1. Barely visible entry wound of the pellet (arrow)**

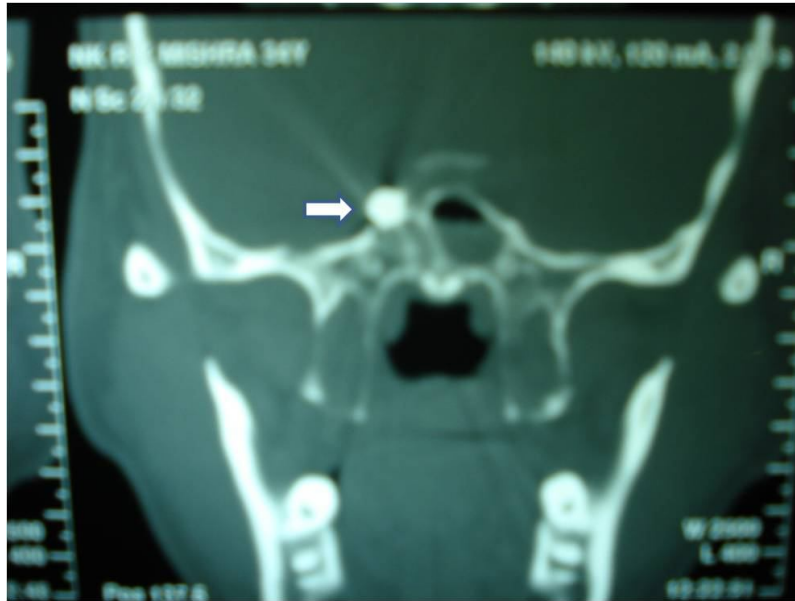


Fig 2. Coronal CT image showing pellet (arrow) in the roof of Rt sphenoid sinus

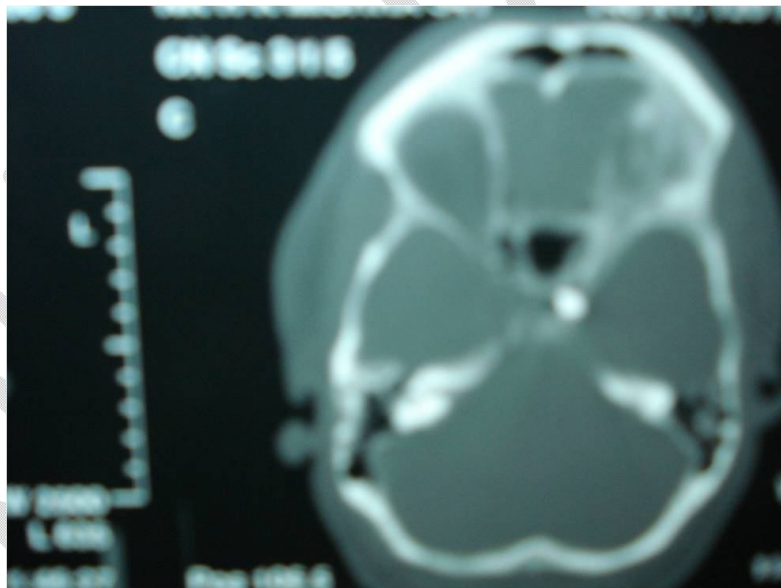
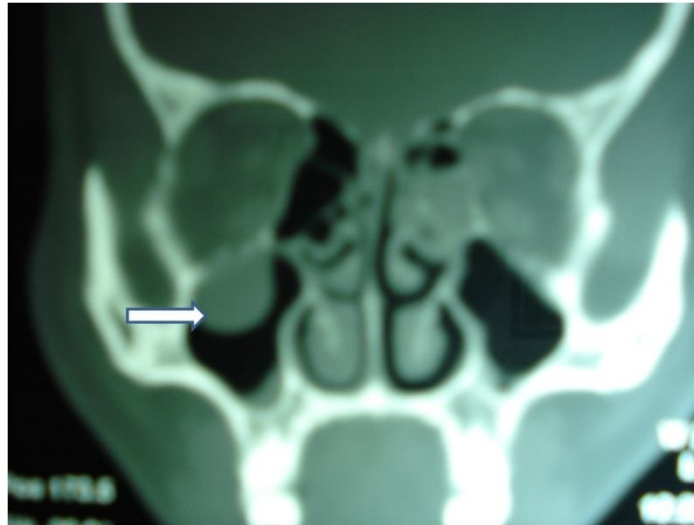

Fig 3. Axial CT image showing pellet by the side of body of sphenoid encroaching cavernous sinus area



**Fig 4. Coronal CT image showing herniation of soft tissue through the floor of Rt orbit (arrow). Destruction of ethmoid cells with air trapping is also seen.**

#### REFERENCES

1. Bratton SL, Dowd MD, Brogan TV, Hegenbarth MA. Serious and fatal air gun injuries: more than meets the eye. *Pediatrics* 1997;100(4):609-12
2. DeCou JM, Abrams RS, Miller RS, et al. Life-threatening air rifle injuries to the heart in three boys. *J Pediatr Surg* 2000;35:785-7
3. Bowen DI, Magauran DM. Ocular injuries caused by airgun pellets: an analysis of 105 cases. *BMJ* 1973;1(5849):333-7
4. Shaw MDM, Galbraith S. Penetrating airgun injuries of the head. *Br J Surg* 1977;64:221-4
5. Burkitt DS, Dhasmana JP, Mortensen NJ, Wisheart JD. "Bullet embolism" to the popliteal artery following air rifle injury of the thoracic aorta. *Br J Surg* 1984;71:61
6. Robson WJ, Kumar K. Air weapon injuries in children: a case for education. *Arch Emerg Med* 1985;2:17-24
7. Abad S, McHenry ID, Carter LM, Mitchell DA: Carotid artery injury from an airgun pellet: a case report and review of the literature. *Head Face Med* 2009; 5:3 doi:10.1186/1746-160X-5-3
8. Ceylan H, McGowan A, Stringer MD: Air weapon injuries: a serious and persistent problem. *Arch Dis Child* 2002; 86(4):234-235
9. Skurczynski W. Air rifle gunshot wounds in the region of the neck and head. *HNO* 1965; 13:223-6
10. Blocker S, Coin D, Chang JHT. Serious air rifle injuries in children. *Pediatrics* 1982; 69:751-4
11. Ford EJ. Air gun injuries in children. *Am Fam Physician* 1987; 36:157-8
12. Montecelli F, Seidl S, Betz P. Air rifle injury with an entrance through the nose: a case report with review of literature. *Int J Legal Med* 2002; 116:292-4
13. Rothschild MA, Schneider V. Gunshot wound to the head with full recovery. *Int J Legal Med* 2000; 113:349-351
14. van As AB, van Deurzen DF, Verleisdonk EJ: Gunshots to the neck: selective angiography as part of



- conservative management. *Injury* 2002, 33(5):453-456
15. Haug RH: Management of low-caliber, low-velocity gunshot wounds of the maxillofacial region. *J Oral Maxillofac Surg* 1989, 47(11):1192-1196
  16. Martinez-Lage JF, Mesones J, Gilabert A: Air-gun pellet injuries to the head and neck in children. *Pediatr Surg Int* 2001, 17(8):657-660
  17. Holland P, O'Brien DF, May PL: Should airguns be banned? *Br J Neurosurg* 2004, 18(2):124-129
  18. Lubianca Neto JF, Mauri M, Machado JR, Cecon A, Paim da Cunha C. Air gun dart injury in paranasal sinuses left alone. *Int J Pediatr Otorhinolaryngol.* 2000 Apr 15;52(2):173-6
  19. Brinson GM, Brent A, Yarbrough WG. Endoscopic management of retained airgun projectiles in the paranasal sinuses. *Otolaryngology Head Neck Surg* 2004; 130(1):25-30
  20. Ben-David J, Podoshin L, Bartal AH. Plasmocytoma arising in the vicinity of a foreign body in the nasal cavity. *Laryngoscope* 1981; 91:1150-4

**<sup>1</sup>Dr (Col) Awadhesh kumar Mishra\*,<sup>2</sup>Dr (Lt Col) Satwinder Pal Singh**

<sup>1</sup>Senior Adviser (ENT), Dept of ENT – HNS, Army Hospital (Research & Referral),

<sup>2</sup>Classified Specialist (ENT), Dept of ENT - HNS Base Hospital,

<sup>1,2</sup>Delhi Cantt, New Delhi -110010, India